

Idiopathic Pulmonary Fibrosis: Case Report and Clinical, Histopathologic and Epidemiologic Attributes

Jerome Santos, MD

Background --- Interstitial lung disease are rare in general, and in our setting, we seldom see cases or we seldom misdiagnosed cases of interstitial lung disease. These are the basic factors affecting the clinical decision making in interstitial lung disease and idiopathic pulmonary fibrosis. Several factors affect our clinical decisions these includes a lack of understanding of the disease itself as well as of its diagnosis and treatment

Case --- We present a case of a 50 year old Filipina who presented with difficulty of breathing and chronic cough for 1 year. Series of Chest X rays showed recurrent pneumonic infiltrates with progressive reticulohazed densities bilateral lung fields. Chest CT scan showed widespread ground glass opacities with persistent reticulohazed densities consistent with Interstitial Lung Disease. Pulmonary Function test confirms a restrictive type of pulmonary disease. Ruling out other causes of Interstitial Lung Disease our patient was diagnosed as Idiopathic Pulmonary Fibrosis. She was managed with corticosteroids and Azathioprine.

Conclusion --- The diagnosis of the different interstitial disease is challenging and is based on a complete and thorough history, clinical symptomatology and diagnostic work ups. However, existing therapies for IPF provides only marginal benefit, and the mean survival ranges from 3.2 to 5 years after diagnosis. *Phil Heart Center J 2008; 14(1):67-75.*

Key Words: Idiopathic Pulmonary Fibrosis ■ Interstitial Lung Disease ■ Corticosteroids ■ Case Report

Interstitial lung disease are rare in general and in our setting we seldom see cases or we can say we seldom misdiagnosed cases of interstitial lung disease. These are the basic factors affecting the clinical decision making in interstitial lung disease and idiopathic pulmonary fibrosis. Several factors affect our clinical decisions these includes a lack of understanding of the disease itself as well as of its diagnosis and treatment In this paper, we present a case of a fifty-year old female who presented with chronic progressive dyspnea and discuss the epidemiologic, histopathologic and clinical aspects of idiopathic pulmonary fibrosis. Included also are the proposed pathogenetic and underlying immunologic mechanisms, review of current medical therapy and summary of new treatment strategies.

Case

This is a case of a 50 year old Filipina who was admitted at Philippine Heart Center because of difficulty of breathing. One year prior to admission, she started to experienced easy fatigability on doing her usual household chores. There was no associated symptoms

thus no consultation was done.

Ten months prior to admission, she started to have exertional dyspnea associated with nonproductive cough. On consultation, chest x-ray done showed haziness of both lower lung fields. She was admitted and treated as a case of Community Acquired Pneumonia-Moderate Risk and Pulmonary Tuberculosis III. She was given Cefuroxime, Azithromycin, Ambroxol and Isoniazid-Rifampicin-Pyrazinamide-Ethambutol (Myrin P forte). She was discharged apparently improved and was advised follow up. She took the anti TB drugs for two weeks only. She was then lost to follow up.

Three months after, there was recurrence of difficulty of breathing and non productive cough. She self medicated with mucolytics and unrecalled antibiotics, which afford temporarily relief of symptoms.

Five months prior to admission, there was progression of dyspnea and paroxysmal dry cough. She consulted another physician. Chest X ray done showed partial clearing of the haziness of both upper lobes. ECG showed nonspecific STT wave changes. She was treated as a case of Hypertensive Cardiovascular

Winner PHC 16th Annual research Poster Competition 2008

Correspondence to Jerome Santos, M.D. Division of Pulmonary Medicine. Philippine Heart Center, East Avenue, Quezon City, Philippines 1100 Available at <http://www.phc.gov.ph/journal/publication> copyright by Philippine Heart Center and H.E.A.R.T Foundation, Inc., 2008 ISSN 0018-9034

Disease with Congestive Heart failure and Community Acquired Pneumonia and was given Diltiazem, Furosemide, Captopril and Levofloxacin which she took for 7 days. No follow up consult done.

A month after, the above symptoms became more progressive and was now associated with anorexia and body malaise. She was admitted and again treated as a case of Community Acquired Pneumonia and was given Cefuroxime 500 mg IV BID and Azithromycin 500 mg/tab, 1 tab OD. Chest Radiograph showed haziness in the right paracardiac area. ABG showed normal acid base balance with adequate oxygenation, CBC, Na, K, Creatinine, Urinalysis, 12 lead ECG and 2D Echo were all normal. She was referred to a Pulmonologist and impression was Pneumonia and T/C Interstitial Lung Disease. She was advised a Pulmonary Function Test and work ups for Connective Tissue disease which she refused. She was then discharged per request after 3 days. No follow up consultation done. Another consultation was done with another physician two months after wherein she was given unrecalled antitussives and antibiotics for dyspnea and dry cough.

Two weeks prior to admission, she consulted with her Pulmonologist due to progressive cough and dyspnea. She was again advised admission but refused and was given oral medication instead (Co amoxiclav and ambroxol) which she took for 7 days. However, her difficulty of breathing became intolerable, thus she was admitted.

Pertinent in her medical history was that she was on Diltiazem for her hypertension (diagnosed 2001), and metformin for her Diabetes Mellitus Type 2 (diagnosed 2000). She had regular annual check up with their insurance (until year 2000) with her previous laboratories and chest radiographs were apparently normal. There was no known allergies.

There was no heredofamilial disease in the family except for hypertension and diabetes. She is a nonsmoker, with no history of passive smoking from members of the family except when she goes outside their house. She is a non alcoholic beverage drinker and no history of intake of prohibited drugs. She is a housewife. She was born in Zamboanga City, however, they transferred to Manila in the early 1970s (when she was 14 years old). They now live in Caloocan City, in a subdivision free from mining, industries, factories and exposure to chemicals.

She is a G3P3 (3003), with menarche at age 16. Subsequent menses were regular an average of 28-30 days, consuming 3-4 pads per day lasting for 3-4 days. No noted gynecological disease and has regular PAPs smear. Patient now had irregular menses occurring every 2 months. Her last check up with an OB-GYN was

3 years ago. Pertinent on the review of systems, she had anorexia, easy fatigability, cough, dyspnea and back pain. Pertinent physical examinations focused on the chest and lungs showed symmetrical chest expansion, absent subcostal, intercostal and supraclavicular retractions, normal tactile and vocal fremitii, crackles on both lung fields from mid to base, inspiratory and expiratory, and no wheezes was noted. The rest of the physical examination was unremarkable.

On admission, she patient was seen conscious, coherent, ambulatory in mild cardiorespiratory distress. She was hook to O₂ at 2LPM/nasal cannula. ABG showed normal acid base balance with adequate oxygenation. Chest xray showed reticulonodular densities on both lung fields. She was started on the following medications: N-acetylcysteine 600 mg/tab OD and Salbutamol nebulization q6 hours. Her antihypertensive drugs as well as her anti diabetic medications were continued. CBC, Na, K, Creatinine, FBS Hg-bA1C, SGPT and Urinalysis done all revealed normal results. ECG showed nonspecific STT wave changes. Admitting Impression was T/C Interstitial Lung Disease, HCVD, DM type II. Chest CT Scan showed widespread ground glass opacities accompanied interstitial thickening and some bronchiectatic changes seen in both lung fields. Impression was T/C Interstitial Lung Disease. She was then started on Prednisone 30 mg per day and Ranitidine 150 mg/tab 2x a day. Pulmonary Function Test was planned, however, she cannot tolerate the procedure. Other laboratory examinations were done, ANA titer, RF factor, CRP, anti dsDna were all negative. She was discharged after 3 days apparently improved and was advised follow up for bronchoscopy and Pulmonary Function Test.

On follow up, flexible Bronchoscopy done was essentially normal save for slight edema of bronchial airways. Bronchial washing, differential count was predominantly neutrophilic, and there was growth of Klebsiella Pneumonia. Bronchial washing cell cytology as well as transbronchial biopsy showed only inflammation and absence of malignant cells. She was then given Ciprofloxacin 500 mg/tab 1 tab BID. Other medications were continued. Pulmonary Function test (Simple Spirometry) showed restrictive lung disease. She is now on her 3rd month of Prednisone, however, apparently with progressive symptoms. Azathioprine was added to her medications.

Discussion

The term interstitial lung disease implies inflammatory fibrotic inflammation of the alveolar walls (septa) resulting in profound effects on the capillary endothelium and the alveolar epithelial cells. It is a disease

describing many entities that injures the lung parenchyma, producing a disease with similar clinical, radiologic and physiological features. However, many interstitial lung disease affect not only the alveolar structures, but also the lamina and the walls of the small airways like the alveolar ducts, respiratory bronchioles and terminal bronchioles. Hence, the term interstitial is a misnomer when the cause of the interstitial lung disease is unknown it is called idiopathic pulmonary fibrosis.

Prevalence and Incidence

The exact prevalence and incidence of interstitial lung disease is unknown, however, it was estimated that the prevalence of interstitial lung disease is 80.9 % per 100,000 for men and 67.2 % per 100,000 for women and the incidence 31.5 % per 100,000 in men and 26.1 % per 100,000 for women.

Morphology And Anatomy

The injury in interstitial lung disease starts with the alveoli and in between the alveoli are the interstitial spaces, which is primarily affected by interstitial lung disease and eventually affecting also the small airways. Normally, the interstitium is composed of interstitial macrophage, fibroblast and myofibroblast. On the other hand, the matrix of the lungs is composed collagen related macromolecules as well as non-collagenous protein, such as fibronectin and laminin. So, as a result of different injurious process, there will be injury to the gas exchange unit, which results to interstitial fibrosis resulting to increase in alveolar permeability. Then, with the leakage of serum contents to the alveolar spaces, eventually, there will be fibroblastic proliferation and excessive collagen deposition. Then, as a direct result of injury (inflammation), there will be regenerative or reparative process, which further increases fibroblastic proliferation and collagen accumulation. These processes, which initially affects the side of the interstitium will also affect the airway lamina.

Interstitial Lung Disease

The diagnosis of the different interstitial disease is challenging. There are almost more than 100 diseases that can cause interstitial lung disease. The diagnosis is based on a complete and thorough history, clinical symptomatology and diagnostic work ups. There are five major classifications, namely, connective tissue disease, drug related or treatment induced, primary disease, occupational and environmental disease and the idiopathic or the cryptogenic type. Under the connective tissue, this could be scleroderma, polymyositis, systemic lupus erythematosus, rheumatoid arthritis,

mixed connective tissue diseases, and ankylosing spondylitis. Drugs that can cause interstitial lung diseases includes antibiotics (nitrofurantoin and sulfasalazine), anti-arrhythmic (amiodarone, tocainide, propafenone), anticonvulsants (diltiazem), anti-inflammatory (gold, penicillamine), and a lot of chemotherapeutic drugs. Among the primary disease, ILD is found in sarcoidosis, amyloidosis, carcinomas, lymphangiomatosis, AIDS and in ARDS. Occupational and environmental lung disease are the more common causes of ILDS and these includes silicosis, asbestosis, coal workers, berylliosis, and farmers' lung. The last classification is when all other causes are ruled out and the cause is unknown. We call them idiopathic pulmonary fibrosis or cryptogenic fibrosing alveolitis (European term).

The causes of ILDS are daunting as enumerated and they are link to by many common features, such as by clinical presentation, by radiological appearance, by physiological abnormalities and histologic findings. Diagnosis of ILD secondary to connective tissue, drug related and occupational may be obvious if we have a complete history. However, the primary and the idiopathic interstitial lung disease are difficult to diagnose on clinical ground alone, so a specific pattern can be diagnosed with a very careful history and laboratory test.

Clinical Presentation Idiopathic Pulmonary Fibrosis is now recognized as a distinct clinical entity. It is a specific form of chronic fibrosing interstitial pneumonia of unknown origin, limited to the lungs and with histologic appearance of usual interstitial pneumonia. Its etiology is still unknown. The estimate prevalence in the US is between 35-50,000 cases. Age of onset is between 40-70 years. It has no geographical, racial and ethnical predilection. Philippine data was so scarce that it was reported in only 20 cases (PGH study). IPF usually presents insidiously with progressive, disabling dyspnea and a non productive cough. Velcro crackles are heard on auscultation in more than 80% of patients. These are characteristically end inspiratory and are most prevalent in the lung bases. Virtually all patients with IPF have an abnormal chest x ray or high resolution computed tomography at presentation. There are peripheral basilar reticular opacities that are usually bilateral and often asymmetric. The typical findings in pulmonary function test are consistent with a restrictive ventilatory defect. Other symptoms that can occur are weight loss, fever, fatigue, myalgia and arthralgia. The presence of fever usually suggests another diagnosis. Patients usually had their symptoms from months to years (12-18 months) at

the time of diagnosis. Clubbing of the fingers, seen in 40%-70% of patients, is usually a late finding. Cardiac examinations is usually normal except in the late stages when there is the presence of pulmonary hypertension and cor pulmonale. Cyanosis is a late manifestation and spontaneous pneumothorax rarely occurs.

Laboratories such as serum chemistries and serology are less useful in the diagnosis of IPF. They are used to rule out other causes of ILD. Usually, there is hypergammaglobulinemia. There should be low titers of ANA, RF, and immune complex, which are increased in the connective tissue type.

Diagnosis

The diagnosis of the specific type of ILD is based mainly on accurate clinical history, laboratory, pulmonary function test, radiography, bronchoscopy, bronchoalveolar lavage, transbronchial biopsy and thoracoscopic and open lung biopsy. In general, ILD have a common clinical, radiologic and physiologic features. Pathognomonic to ILDs is the presentation of progressive dyspnea and dry cough, impaired pulmonary function test, an abnormal chest radiograph and an abnormal CT scan. For the diagnosis, a complete history is very important and relevant because by history alone we can have a probable diagnosis. Our history, which includes the past medical, family history, occupational, family, drugs, personal and social histories, should be in depth. In our case, the clinical presentation is consistent with the typical presentation of ILD: progressive dyspnea, dry cough, characteristic chest radiographic and CT scan findings and restrictive pattern on pulmonary function tests. Since there is unremarkable past medical, family, personal and social, and occupational history as well as absence of intake of drugs that can cause ILD, the presentation is most likely due to idiopathic pulmonary fibrosis. Ancillary tests (such as ANA, RF, dsDNA) were all negative, thus ruling out the usual etiology for ILD. So, when all things are ruled out, we could have here an idiopathic type of lung disease. What is missing in our approach to diagnosis is the gold standard or the definite diagnosis, which can be achieved by a lung biopsy, a surgical lung biopsy via thoracoscopy or open lung biopsy. However, there are present guidelines which diagnosed IPF without the benefit of biopsy.

Radiology

Chest radiography usually demonstrate any of the following pattern: a reticular and netlike appearance of linear or curvilinear densities or diffuse opacities with a predilection to the lower lobes. In advanced disease, the presence of a coarse reticular pattern or multiple

cystic or honeycombed areas, and coarse reticular pattern with translucencies are associated with poor prognosis. Pleural involvement is uncommon and its presence suggest another diagnosis. HRCT is the imaging of choice and is useful in differentiating IPF from other causes of ILDS. It can also determine the extent and severity of the disease and most importantly their detection, especially in patients with normal or minimal change on plain chest radiograph. We could see marked peripheral and subpleural distribution of the interstitium. The involvement is patchy with areas of reticulation intertangled with areas of normal tissue. In early disease, they appear as patchy peripheral, subpleural reticular opacities with minor degree of honeycomb change. On the other hand, in advanced disease, there is a diffuse reticular pattern prominent in the lower lung with thickened interlobar septal and intralobular lines.

Orens and colleague showed that the accuracy of HRCT in diagnosing IPF has a sensitivity of 43-78% and specificity of 90-97%. They also concluded that the ground glass appearance in HRCT signifies cellular inflammation, whereas reticular pattern signifies fibrosis.

Gay and colleague also develop an HRCT interstitial scoring which predicts mortality.

- 0 no interstitial disease
- 1 interlobular septal thickening, no discrete honeycombing
- 2 honeycombing involving up to 25% of the lobe
- 3 honeycombing involving up to 25-49% of the lobe
- 4 honeycombing involving up to 50-75% of the lobe
- 5 honeycombing involving up to >75% of the lobe

Final score is the mean score from each lobe. A score of more than 2 predicts mortality with 80% sensitive and 80 % specific. The consensus noted that virtually all patients with IPF have an abnormal chest radiograph at presentation. Basal reticular opacities are characteristic but not diagnostic. Compared with chest radiograph, HRCT scanning increases the level of diagnostic confidence. The accuracy of a confident diagnosis of IPF made on HRCT by a trained radiologist appears to be 90%.

Wells and colleague analyzed the predictive value of reticular and ground glass abnormalities in HRCT. In patient with IPF, the presence of predominantly ground glass appearance is associated with greater improvement in lung function and a better prognosis. In contrast, a predominantly reticular pattern is associated with relatively little improvement in lung function

and a poorer prognosis.

Other imaging studies that can be use are gallium scanning and ventilation perfusion scanning.

Pulmonary Function Test And Lung Volume Studies

Pulmonary function test will show a restrictive type of lung disease. The lung volumes (total lung capacity, functional residual capacity, residual volume) are decreased. In the early stage of the disease, lung volumes can be normal, the expiratory flow rates (FEV1 and FVC) are reduced because of reduction of lung volumes, but the FEV1/FVC ratio is maintained or increased. These pattern were seen in our patient where the FVC is severely decreased and the FEV1 is moderately decreased and the FEV1/FVC ratio is normal/increase. There is also increased elastic recoil in our patient and the flow rates are usually increased. Patient with IPF are usually tachypneic, with rapid shallow breaths, because of increased work of breathing as a result from altered mechanical reflexes, cause by the increased elastic load, vagal mechanism, or both.

DLCO is reduced as a result from both the contraction of the pulmonary capillary volume and the presence of ventilation-perfusion abnormalities. The resting arterial blood gas is usually abnormal and reveals hypoxemia and respiratory alkalosis, which is caused by ventilation-perfusion mismatch and not due to either impaired oxygen diffusion or shunts.

Pulmonary hypertension occurs in advanced disease and it usually occurs when the vital capacity is less than 50% of predicted or the DLCO is less than 45% of predicted, the mean pap at rest is 24-28 mmHg. The cause of pulmonary hypertension is multi-factorial: compression and destruction of the pulmonary vessels; interstitial infiltrative process; and vasoconstriction of the vessels mediated by hypoxia, acidosis and autacoids.

Bronchoscopy / Broncho Alveolar Lavage (BAL)

Examination of the BAL fluid has been used to predict responsiveness to steroids as well as overall prognosis. For example, a relatively high levels of surfactant in BAL fluid are associated with good prognosis and relatively high levels of pro collagen peptides are associated with improved gas exchange and increase lung volumes. Excess neutrophils and/or eosinophils (>5%) in BAL fluid have been associated with a higher likelihood of disease progression and a failure to respond to immunosuppressant. Ross and co workers analyzed BAL of 120 patients with IPF. A higher percentage of lymphocytes in BAL fluid is associated with a greater steroid response, whereas a high percentage of neutrophils

predicts no responsiveness to steroids.

Histopathology

Until the 1990s, the term idiopathic was applied to a heterogeneous group of processes that included a number of histopathologic patterns. More recently, these histopathologic patterns have been separated as distinct entities but are grouped together under the heading of idiopathic interstitial pneumonia. Usual interstitial pneumonia is the usual histopathologic corollary of IPF. The other histopathologic pattern includes desquamative interstitial pneumonia, respiratory bronchiolitis associated ILD, acute interstitial pneumonia (Hamman-Rich Syndrome) and the nonspecific interstitial pneumonia.

Surgery and Biopsy

Surgical lung biopsy is the current standard for diagnosis. If the transbronchial biopsy, clinical, and HRCT are inconclusive and the patient is not a high risk, a open lung biopsy via VATS or open thoracotomy must be performed to have a definite histologic diagnosis and to exclude neoplastic and infectious process that occasionally mimics the chronic progressive interstitial disease.

According to the consensus (see below), surgical lung biopsy may be deferred if you fulfill the 4 major and at least 3 out 4 minor clinical criteria in the diagnosis of ILD. Lung biopsy has its risk and these is seen in advanced age, extreme obesity, concomitant cardiac disease, extreme impairment of lung function and emphysematous lung with the presence of bullae.

Guideline and Consensus

The American Thoracic Society (ATS) and the European Respiratory Society (ERS), in collaboration with the American College of Chest Physicians (ACCP) published an international consensus and statement on the diagnosis and treatment of IPF. These statement emphasize that the definite diagnosis of IPF requires a surgical lung biopsy showing the usual interstitial pneumonia, which is an idiopathic progressive diffuse fibrosing process involving the lung parenchyma. A surgical biopsy is recommended in patients with suspected IPF with no contraindication to surgery and for whom the potential benefits outweigh the surgical risk. The major purpose of histologic examination is to distinguish UIP from other histologic subsets of IIP. However, because of the risk of doing a biopsy, the ATS/ERS/ACCP provided a guideline that states that a biopsy may not be needed to fulfill the criteria for diagnosis, which includes presence of the four major criteria and three out of four minor criteria. The major

criteria includes the following: exclusion of other known causes of ILD; abnormal pulmonary function studies; bibasilar reticular abnormalities on HRCT scan and no histologic or cytologic features on transbronchial lung biopsy or BAL analysis supporting another diagnosis. On the other hand, the minor criteria are as follows: age >50 years; insidious onset of otherwise unexplained exertional dyspnea; duration of illness ≥ 3 months; and bibasilar, dry (“Velcro”) inspiratory crackles. Our patient fulfilled 4 out of the 4 major and 4 out of 4 minor criteria.

The histological landmark, and chief diagnostic criterion in IPF is a heterogeneous appearance with alternating areas of normal lung, interstitial inflammation, fibrosis and honeycomb changes. The fibrotic zone is composed mainly of collagen.

Pathogenesis

When there is a multiple injuries and damage to alveoli, there will be activation of the alveolar epithelial cells, which induce an inflammatory and antifibrinolytic environment in the alveolar space, enhancing wound clot formation. The alveolar epithelial cell then secretes growth factors and induce migration and proliferation of fibroblast and differentiation into myofibroblast, which interacts. Increase basement membrane disruption allows further fibroblast proliferation, neovascularization, further collagen deposition. Thus, further damage occurs to the lung interstitium and eventually involves the rest of the respiratory unit.

Fibroproliferation

The normal repair process in response to a triggering lung injury begins with a cellular phase which is associated with inflammation and induction of leukocyte hominin and trafficking by a preponderance of cytokines. This is followed by granulomatous tissue formation, including angiogenesis, deposition of extracellular matrix and fibroproliferation. Healing occurs with re-epithelialization and establishment of the normal homeostatic relationship among parenchymal cells, stromal cells and the extracellular matrix. In IPF, the progressive fibrotic phase replace homeostasis. There is an abnormal repair process characterized by persistent chronic inflammation, fibroproliferation, angiogenesis and exuberant deposition of extracellular matrix. These events leads to a loss of normal functional relationship among parenchymal, stromal and the extracellular matrix. The inflammatory response is characterized by recognition, recruitment, removal and resolution (repair). During recognition, there is increased expression of adhesion molecules for leukocyte trafficking, which leads to fibroblast expression,

proliferation and migration.

Treatment

Existing therapies for IPF provides only marginal benefit. Conventional approaches to treatment includes drugs with anti-inflammatory activity, such as corticosteroids and immunosuppressives and cytotoxic agents, including azathioprine and cyclophosphamide and anti-fibrotic agents such as colchicine and d-penicillamine, either alone or in combination for a minimum of 6 months. Interferon, a cytokine whose production is impaired in IPF, inhibits the proliferation of fibroblast, and its use has been studied in patients with IPF to counterbalance the effect of fibroproliferative process. The validity of earlier trials and the ability to compare results. among these trials were limited for a number of reasons these includes the relatively small number of patients enrolled, variable natural history and clinical course of the disease, heterogeneous nature of study population, variable and non validated assessment criteria variable duration of studies and the frequent absence of placebo controls.

The rationale of treatment is based on the concept that inflammation leads to injury and fibrosis. The medications are used to reverse or modify this processes. However, in ILD, fibrosis of the lung parenchyma is irreversible and eventually gas exchange is damaged resulting to respiratory insufficiency and eventually death.

Corticosteroids are the mainstay of therapy. The response to corticosteroids is usually poor and the short term improvement is appreciated in only in a minority of patient. The long term improvement is poor (8-10%). The usual dose is 40-100 mg/day and the dose and the rate of tapering is guided by clinical and physiologic parameters. However, its use has many complications such as fatigue, weakness, arthralgia, anorexia, nausea, desquamation of the skin, orthostatic dizziness, hypotension, fainting, hypo- and hyperglycemia. The next drug in line is azathioprine. It is a purine analogue that acts by substitution of purines in DNA synthesis and inhibition of adenine deaminase, which affects lymphocytes. It has a cytotoxic effects and is use for steroid non-responders or those with side effects with steroid use. It also suppresses the production of autoantibodies. The dose is 2 mg/kg. Its side effects are usually hematologic and gastrointestinal. Cyclophosphamide is a second line drug that is use for those who have failed to benefit from steroids and azathioprine. It is an alkylating agents and its mode of action is depletion of lymphocytes and inhibition of inflammatory process. Dose begins at 2-5 mg/kg/day and its side effects is leucopenia and hemorrhages.

Raghu and associates compared the effect of azathioprine plus prednisone on lung function with that of prednisone alone in previously untreated patients with IPF. They have shown that 43% of patients randomized with azathioprine plus prednisone died during the 9 year follow up, as compared with 75% of patients randomized to prednisone alone.

Douglas and colleague compared the pulmonary function of 22 patients with IPF who were treated with colchicine alone compared with prednisone alone. Failure was defined as a decline in 15% of FVC and a decline in 30% of DLCO from baseline. There was no significant difference in the rate of decline in lung function. There was however a trend toward a more rapid decline in the prednisone group.

Seman and coworkers examined 56 IPF patients who received prednisone alone, prednisone plus colchicine, prednisone plus penicillamine or prednisone plus colchicine and penicillamine. There is no significant difference in survival between patients treated with the anti-inflammatory agents prednisone and those treated with combination of prednisone and the anti-fibrotic agents colchicine and penicillamine. Neither the anti-fibrotic agents modified the course of prednisone treated IPF.

Although current therapy for IPF has been less than successful, molecular biological approaches have provided substantial insights into the pathogenesis of IPF. As a result a wide range of potential mediators of inflammation and fibrosis have been identified and some of these are now the focus of clinical researches. One well studied mediator is the use of interferon. Interferon was employed for patients with steroid-resistant IPF. The interferon trial is now on stage III, with a large number of well-defined study patients needed to confirm potential benefits of IFN- γ 1b in steroid-resistant IPF.

As a conclusion for therapy, most treatment strategies nowadays have been based on eliminating or suppression of the immune response and the inflammatory response. There are no pharmacological therapy that has been proven unequivocally to alter or reverse the inflammatory process in IPF. There is little information that has appeared supportive of the theory that the fibroblastic process can be reversed. However, until no further development, the consensus still recommends the use of a combination of drugs, combination therapy of corticosteroid therapy at a dose of 0.5/mg/kg/day for 4 weeks, 0.25/mg/kg/day for 8 weeks, taper to 0.125/mg/kg/day every other day and azathioprine at dose

of 2-3 mg/kg/day or cyclophosphamide at a dose of 2-5 mg/kg/day. There is no recommendation on when to start therapy. However, they concluded that the earlier the initiation the better is the outcome. There is also no recommendation on the length of treatment. Results usually are appreciated after 3-6 months of treatment and patient should be assessed after 6-12-18 months of treatment. Treatment response is categorized as favorable, stable and failure. Favorable are those with decrease in symptoms, reduction of parenchymal abnormalities, and physiological improvement of lung functions. Stable are those with no change from baseline clinical and physiologic characteristics. Failure are those with increase in symptoms, increase in opacities and deterioration of lung function.

Survival

In the early clinical trials, patients diagnosed with IPF had a mean survival ranging from 3.2 to 5 years after diagnosis. Many of these patients undoubtedly have ILD other than IPF. In a more recent study involving 74 patients with better defined IPF, the median period of observation was 45.8 months from onset of respiratory symptoms. The median survival of the patients who died during this period was 28 months from symptom onset. The apparent decline in survival reflects the poorer prognosis of IPF as compared with other interstitial lung disease. In patients with IPF, functional status inevitably declines. Although clinical deterioration is most frequently due to progressive pulmonary fibrosis, it may result from other causes. The cause of the clinical deterioration is often unclear and disease progression is difficult to distinguish from complications of the disease and adverse effects of treatment.

Panos and colleague found that the most common cause of death among IPF patients is respiratory failure (39%). Other cause of death include lung cancer (10%), pulmonary emboli (3%), pulmonary infection (3%) and cardiovascular disease (27%). Several factors have been found to be predictive of shortened survival in patients with IPF and these includes older age (>50 years at presentation), male gender, severity of dyspnea on presentation, current or previous smoker, more severe lung function derangements, presence of increased neutrophils or eosinophils in BAL fluid, greater extent and severity of reticular opacities and honeycomb changes on the initial HRCT scan, lack of initial response to steroids and histopathologic abnormalities showing more fibrosis and prominent fibroblastic foci.

Relatively preserved lung function is a predictor of longer survival among patients with IPF. Tukianem and associates retrospectively analyzed data from 100 consecutive patients with IPF. They determined that patients with a total lung capacity of 45% had a significant probability of survival than those with < 45%. Schwartz and co workers demonstrated that the reduced survival in patients with IPF was significantly related to a ratio of force expiratory volume in 1 seconds / FVC ratio above the 50th percentile.

Lung Transplantation

Lung transplantation has been recently been offered with IPF and it best done in young individuals. A single lung transplant is the preferred procedure. The ATS guidelines for IPF recommends that transplantations should be considered in the following cases: in symptomatic patients; progressive disease with failure to improve or maintain lung function while being treated with steroids after 12 months; if pulmonary function is abnormal even though the patient is minimally symptomatic; and in asymptomatic patients with abnormal lung function when the vital capacity is below 60% of predicted or the DLCO is 50% of predicted. The prognosis after transplant is that there is a 5 year survival rate of 50-55%. Graft failure, cardiac failure, infection and development of malignancy are the most common cause of mortality.

Pulmonary Rehabilitation

Other issues that are of prime importance is whether we should still subject our patient to pulmonary rehabilitation. The purpose of pulmonary rehabilitation is to restore the possible highest functional capacity. However, less data are available because most of the patients stopped the program because of progressive deterioration of lung function. Another is the need for supplemental O₂ therapy, in the late stages of the disease or when there is development of hypoxemia. Studies on the use of antitussives agents N-acetylcysteine in IPF has been promising wherein the antioxidant property benefits IPF has been investigated. A study done by Ramus and coworkers employed the use of N-acetylcysteine with prednisone and azathioprine using a dose 600 mg three times a day. There was significant improvement in the vital capacity and DLCO in patients with IPF.

Summary

In summary, we have presented a case of 50 years old female, who presented with more than a year history of progressive dyspnea and cough and diagnosed with interstitial lung disease, specifically idiopathic pulmonary

fibrosis, after ruling out other causes of ILD via a thorough medical history, characteristic patterns on chest radiograph and HRCT, restrictive pattern in PFT, and BAL. We have also presented the latest ATS/ERS/ACCP guidelines in the diagnosis and management of IPF, diagnosis without the benefit of a lung biopsy and new treatment approaches in IPF management. Our patient is now on her third month of prednisone and azathioprine but despite the treatment she is progressively deteriorating.

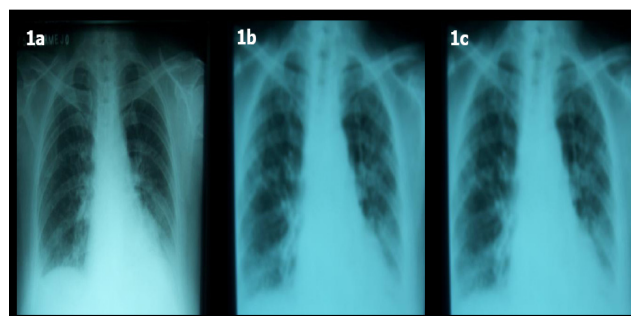


Figure 1. Serial chest films of 50-year old female who presented with progressive dyspnea. 1a. Initial chest film showed haziness on bilateral lower lobes. 1b. Follow-up film showed partial clearing of infiltrates noted on both lower lobes. 1c. Presence of nodular and reticulohazied densities is seen in chest film taken five months after the previous x-ray. (see text for details.)

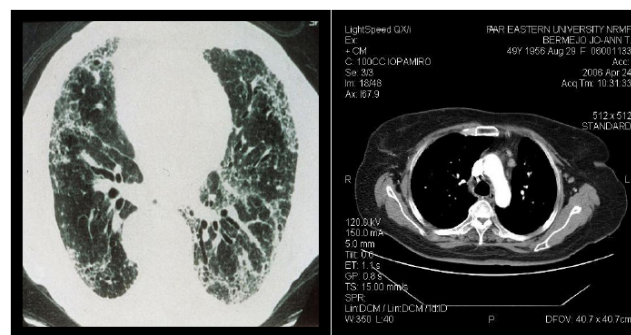


Figure 2. Chest CT scan done on admission. Widespread ground glass opacities accompanied by interstitial thickening and some bronchiectatic changes are seen in both lung fields more severe on the left and in both posterobasal segments. Paraseptal emphysematous changes are likewise seen, more pronounced in both lung bases. A bullae noted in the right posterobasal segment. (see text for details).

Reference

1. E. Wood and J. David Godwin, Ganesh Raghu, Yolanda N. Mageto, Diane Lockhart, Rodney A. Schmidt, Douglas, DOI: 10.1378/chest.116.5.1168, *Chest* 1999;116:1168-1174, The Accuracy of the Clinical Diagnosis of New-Onset Idiopathic Pulmonary Fibrosis and Other Interstitial Lung Disease: A Prospective Study
2. Charlie Strange, DOI: 10.1378/chest.125.1.272, *Chest* 2004;125:272-274 Top Ten List in Interstitial Lung Disease

3. HY Reynolds, Chest 1998;113:192-202 Diagnostic and management strategies for diffuse interstitial lung disease
4. American Thoracic Society, Am J Respir Crit Care Med Vol 161. pp 646–664, 2000 Idiopathic Pulmonary Fibrosis: Diagnosis and Treatment, International Consensus Statement
5. American Thoracic Society, Am J Respir Crit Care Med Vol 165. pp 277–304, 2002 American Thoracic Society/ European Respiratory Society International Multidisciplinary Consensus Classification of the Idiopathic Interstitial Pneumonias
6. L. Welker*, R.A. Joëres*, U. Costabel#, H. Magnussen* Predictive value of BAL cell differentials in the diagnosis of interstitial lung diseases
7. G.M. Verleden*, R.M. du Bois#, D. Bouros}, M. Drentz, A. Millar\$, J. Müller-Quernheimf, G. Semenzato**, S. Johnson, G. Sourvinos}, D. Olivieri, A. Pietinalhozz, A. Xaubet Genetic predisposition and pathogenetic mechanisms of interstitial lung diseases of unknown origin
8. Murray and Nadel Edition IV, Intesrtitial Lung Disease